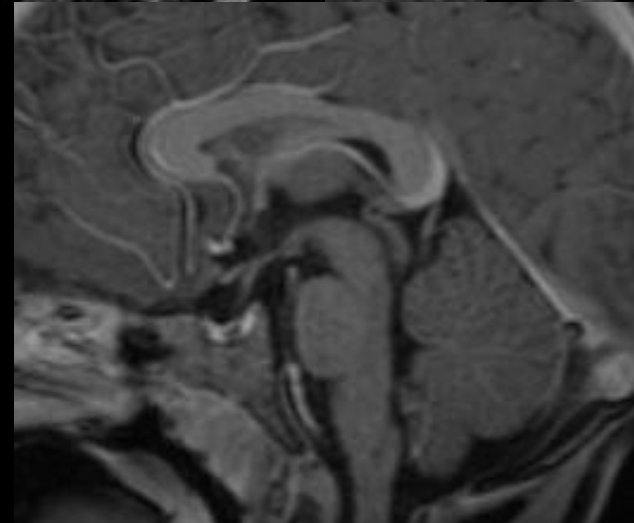
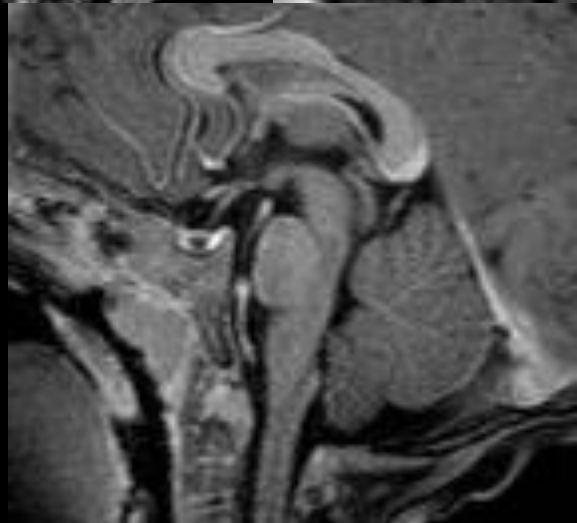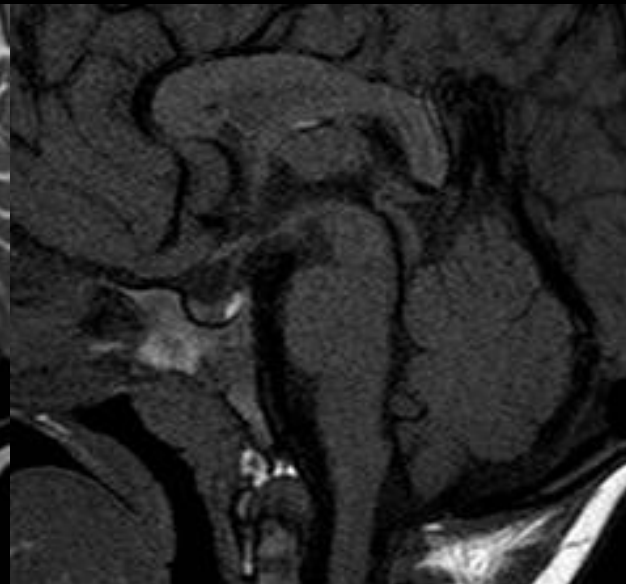
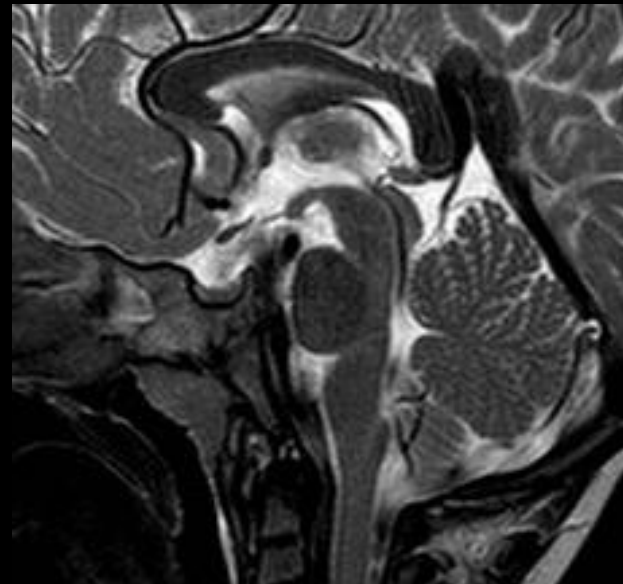
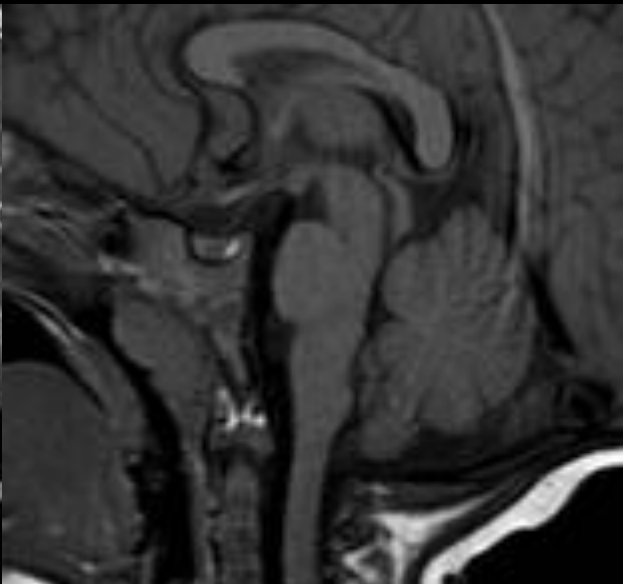

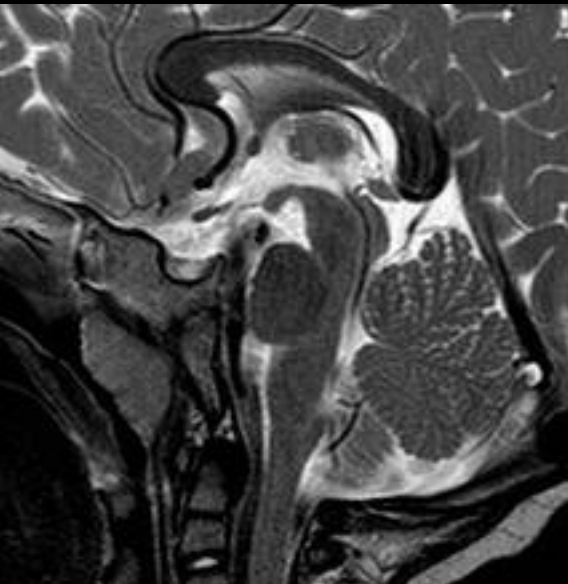
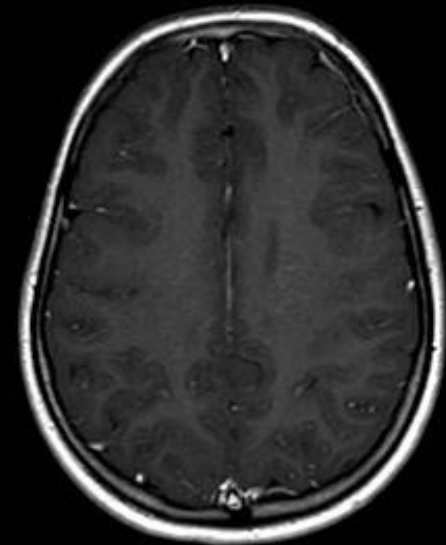
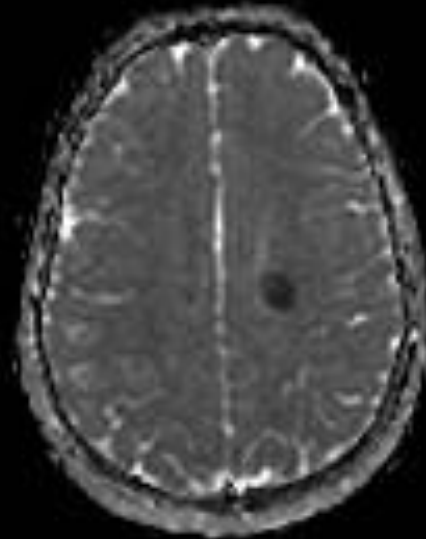
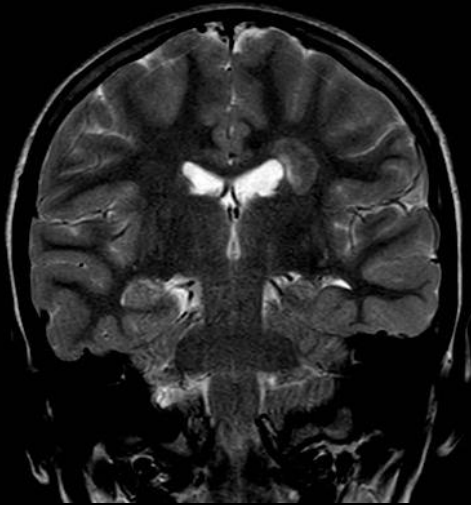
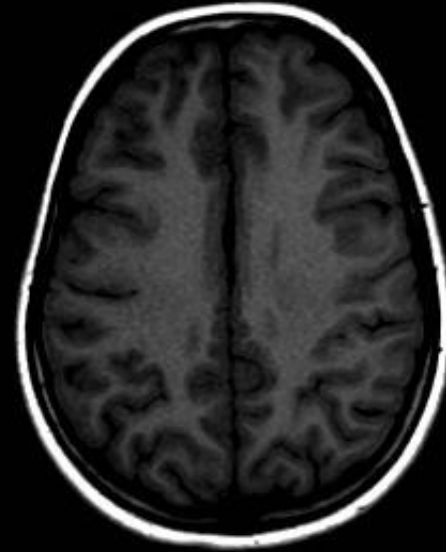
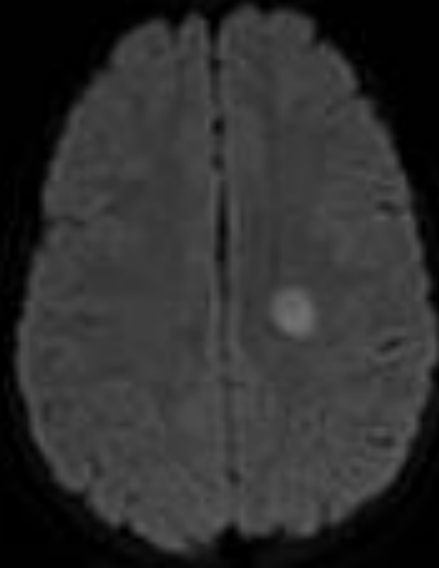
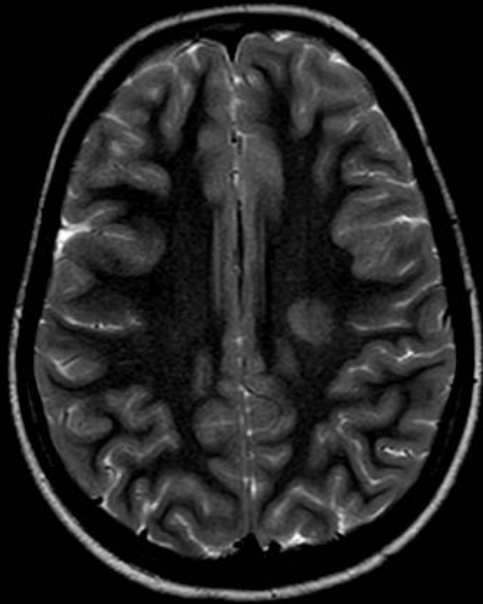
Gennaio 2018

CASO 1

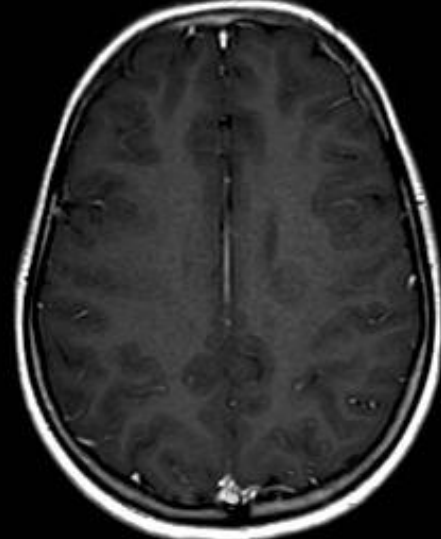
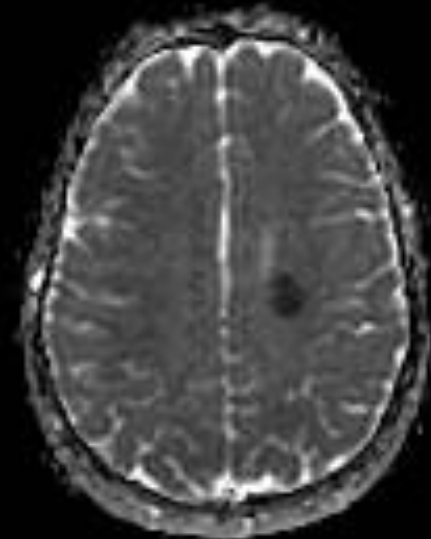
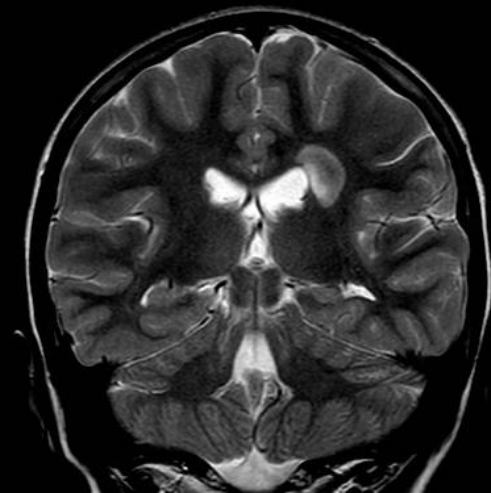
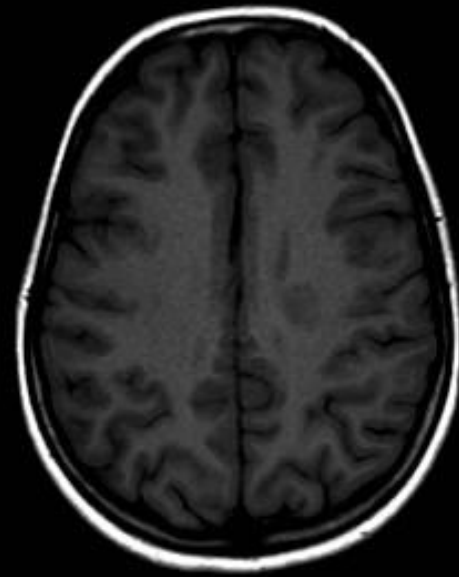
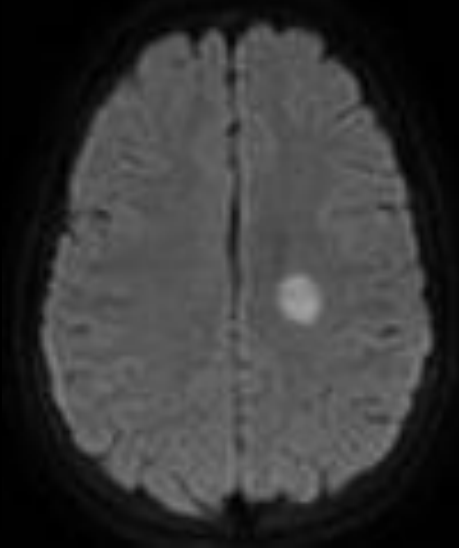
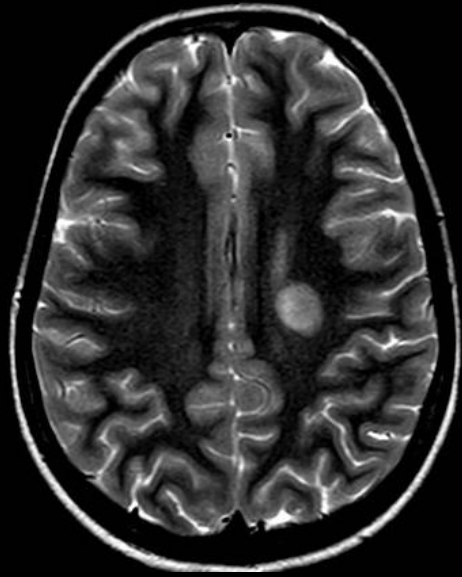
Febbraio 2019



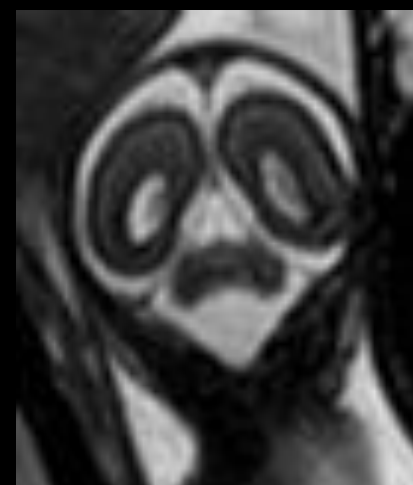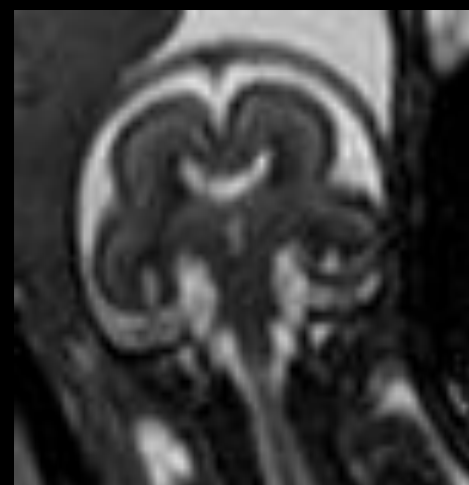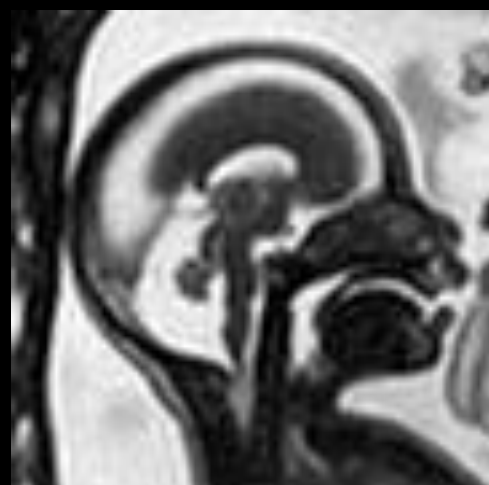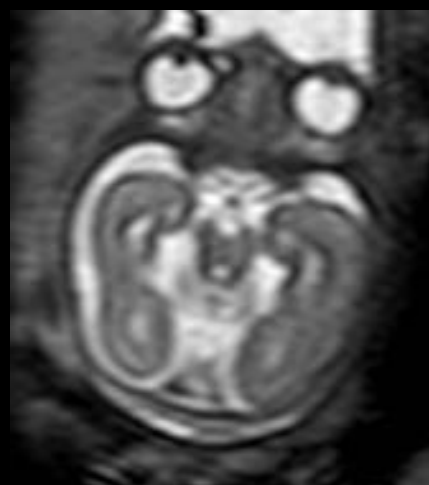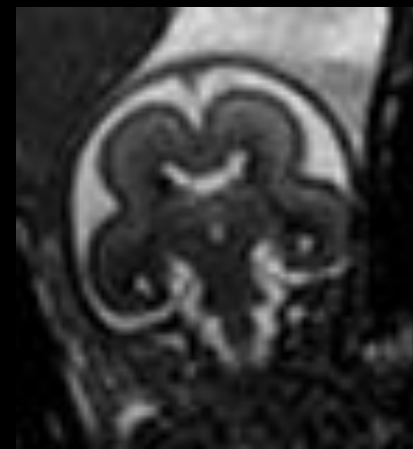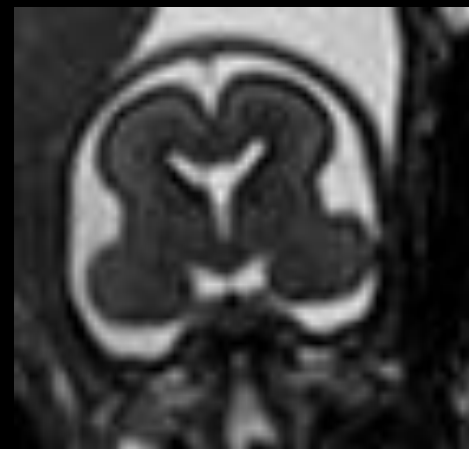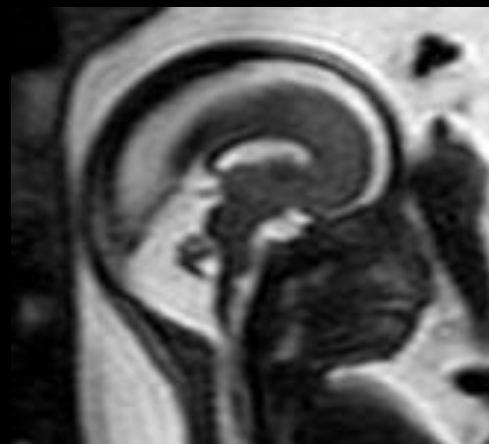
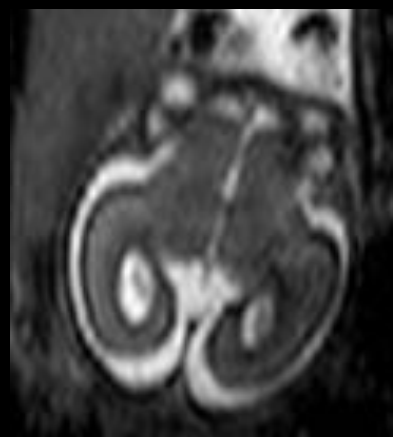CASO 2: 29 gennaio



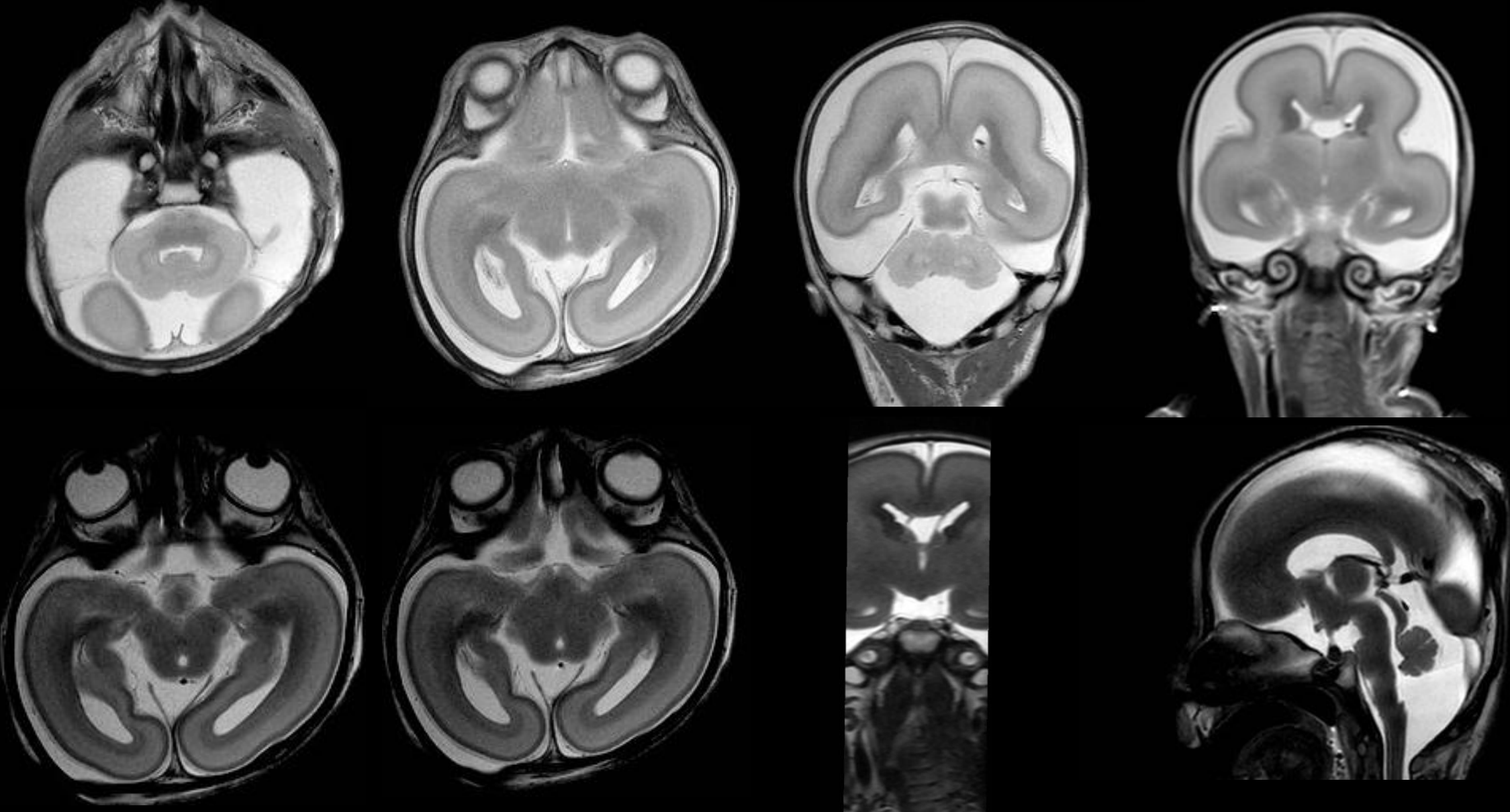
CASO 2: 6 febbraio



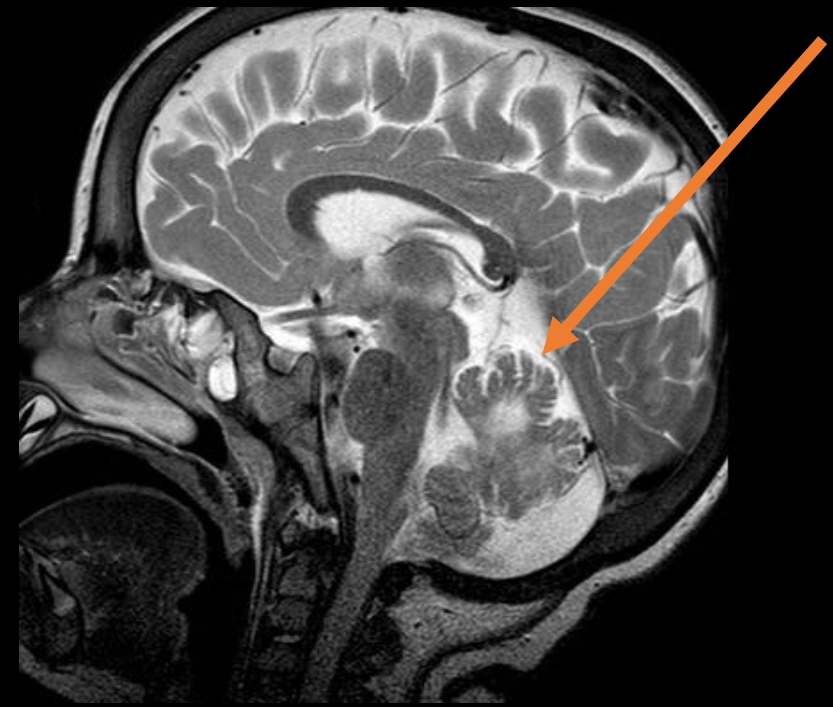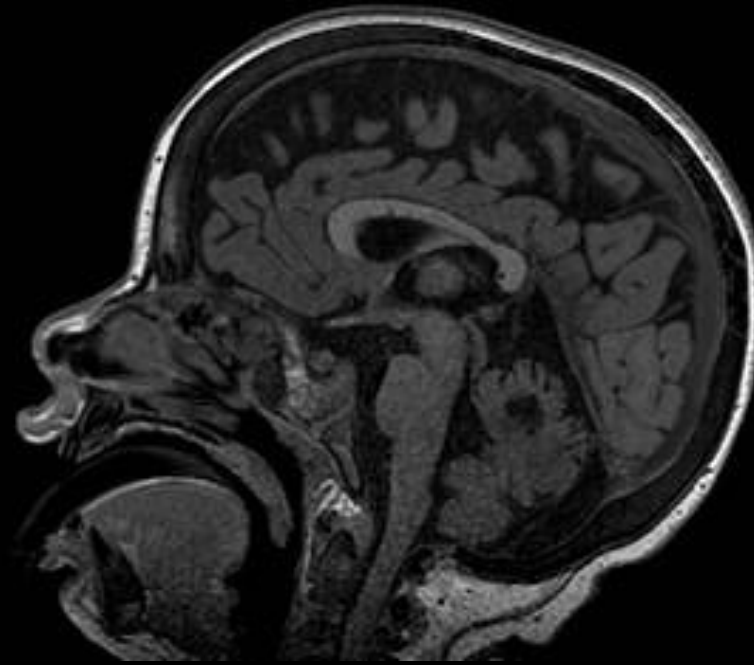
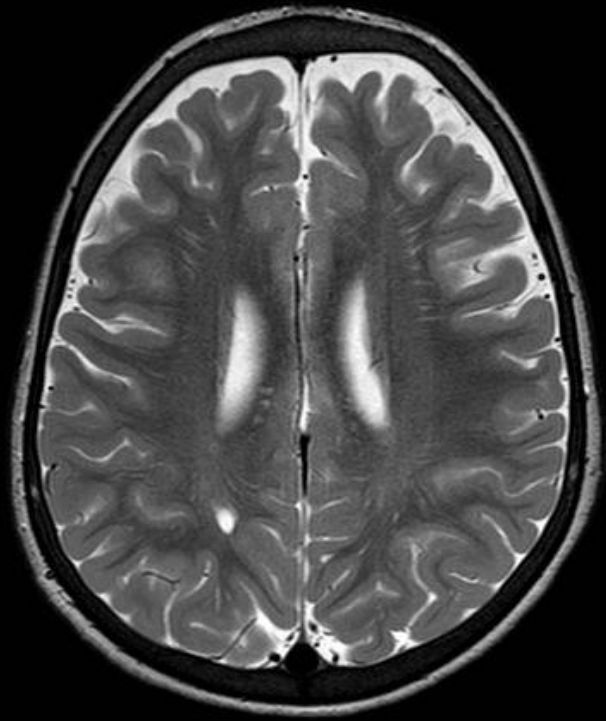CASO 3: RM fetale



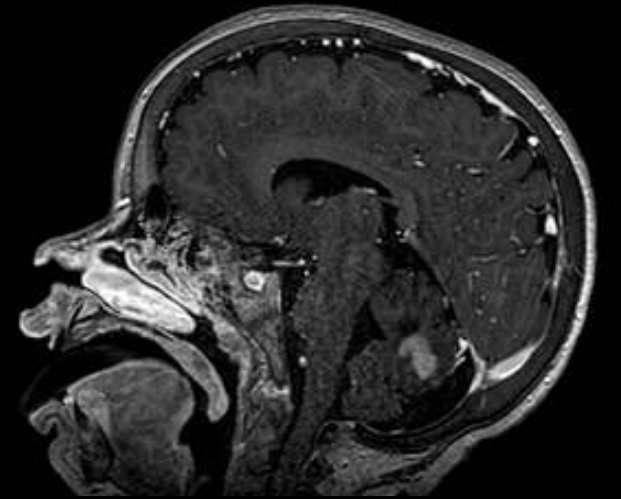
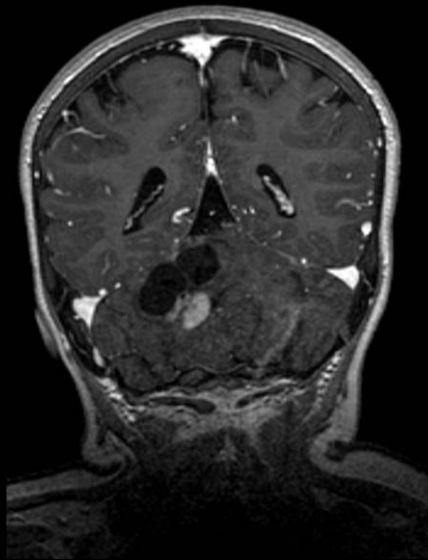
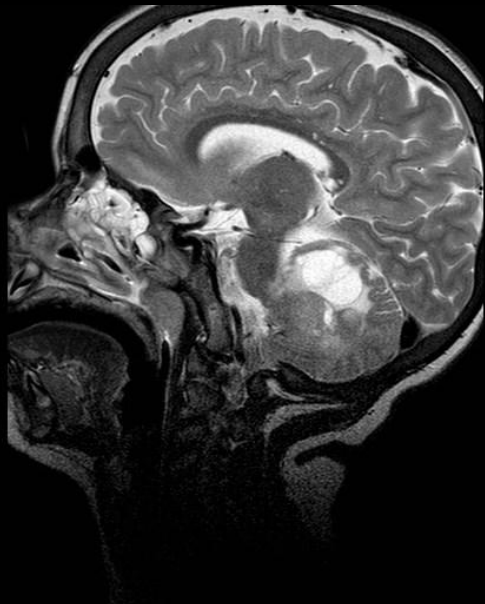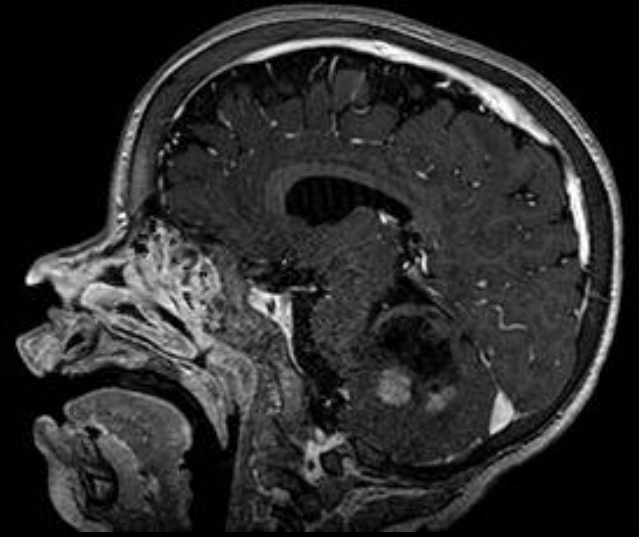
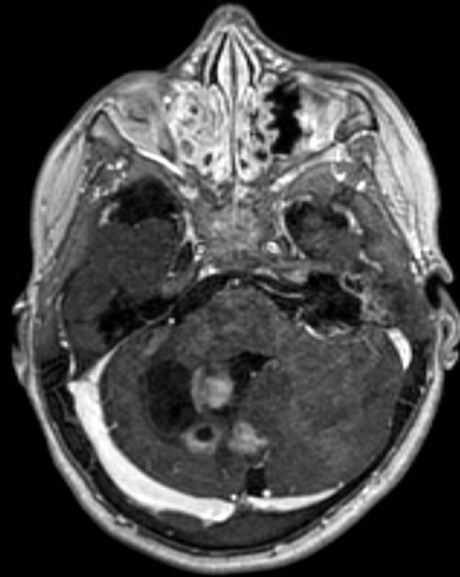
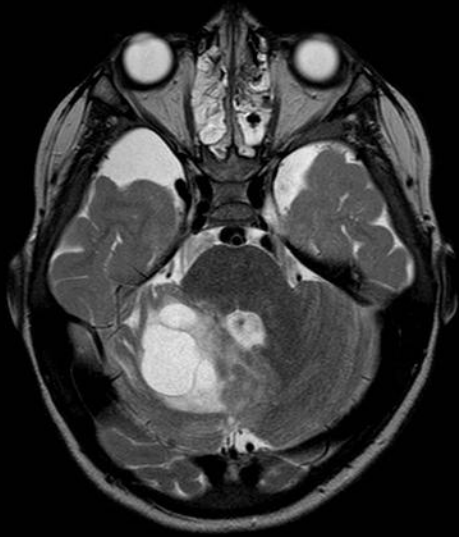CASO 3: RM autopsy



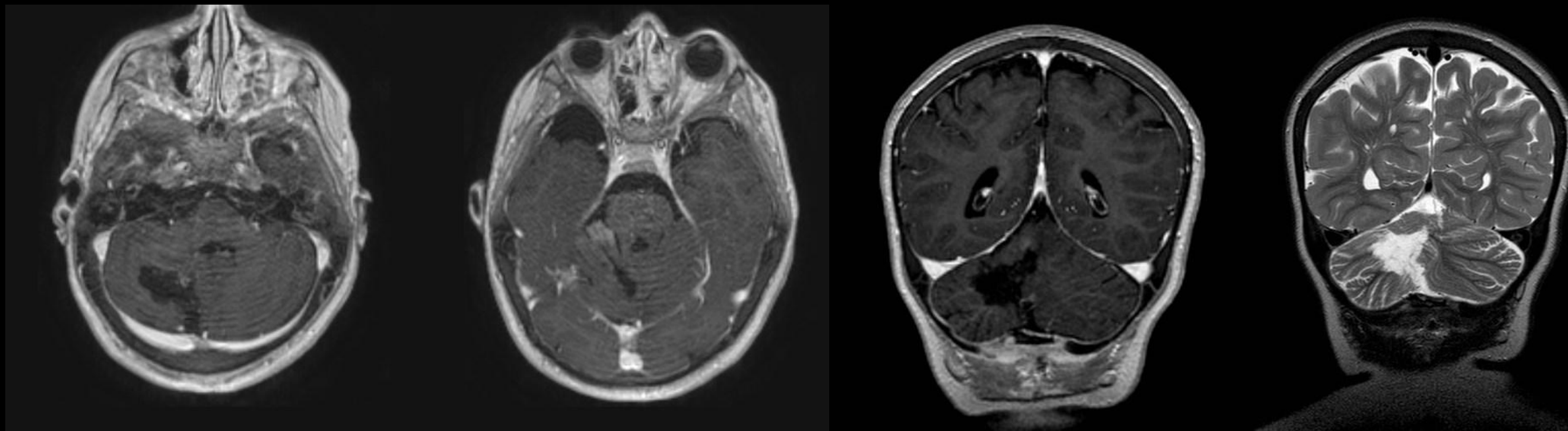
CASO 4



CASO 4



CASO 4: RM post-operatoria



CASO 5

